

Thrombin Injection Failure with Subsequent Successful Stent-Graft Placement for the Treatment of an Extracranial Internal Carotid Pseudoaneurysm in a 5-Year-Old Child

R. D. Garcia-Monaco · A. A. Kohan ·
M. P. Martinez-Corvalan · N. Cacchiarelli ·
O. Peralta · C. G. Wahren

© Springer Science+Business Media, LLC and the Cardiovascular and Interventional Radiological Society of Europe (CIRSE) 2011

Abstract Internal carotid artery pseudoaneurysm is a rare life-threatening condition that may develop in different clinical situations. We report the case of an extracranial internal carotid artery pseudoaneurysm secondary to a throat infection in a pediatric patient that was initially treated with percutaneous thrombin injection under ultrasound guidance. However, recanalization occurred at 48 h, and definitive treatment was then performed by endovascular stent-graft placement. We briefly review the clinical characteristics of this uncommon clinical condition as well as the treatment options.

Introduction

Internal carotid artery (ICA) pseudoaneurysm (PSA) was first described as a complication of a deep space neck infection by Liston in 1843 [1]. Although a rare complication after the discovery of antibiotics, an extracranial ICA PSA may still occasionally develop after a throat infection. This lesion left to its natural course may lead to a massive life-threatening hemorrhage [2–4].

The most common symptoms associated with extracranial ICA PSA are neck swelling, Horner's syndrome, lower

cranial nerves palsy, epistaxis, and a protruding pharyngeal mass [5]. Causes of extracranial ICA PSA are multiple, including blunt or penetrating trauma, iatrogenic injury, carotid dissection, local tumor invasion, and deep neck infection among others [3, 6]. Diagnosis of this disease relies primarily on clinical suspicion followed by imaging confirmation by ultrasound (US) and/or computed tomography (CT) scan.

Extracranial ICA PSA has been treated by surgical carotid arterial ligation for many years since first described, but alternative interventional treatment options have been introduced in recent years [3, 6, 7]. We describe our therapeutic failure with thrombin injection and subsequent success with stent placement in a 5-year-old child presenting with an extracranial ICA PSA secondary to a throat infection. An institutional review board exemption letter was obtained through our hospital research ethics committee.

Case Report

A 5-year-old boy with an 8-month history of adenoidectomy and tympanostomy tube insertion presented to an outpatient clinic with sore throat and cervical pain. Physical examination revealed mild fever, erythematous pharynx mucosa, and bilateral enlarged cervical lymph nodes. Oropharyngeal cultures were negative, and the patient was medicated with NSAIDs. Because symptoms persisted at 48 h follow-up, he was treated with antibiotics (amoxicillin/clavulanic acid 400 mg, 3 times per day) for 10 days. Symptoms rapidly resolved, but a week later he presented to the emergency room (ER) at another institution with bilateral epistaxis that required intravenous (IV) volume reposition. After keeping him in observation for several hours, he was discharged.

R. D. Garcia-Monaco · A. A. Kohan (✉) · O. Peralta
Department of Radiology, Hospital Italiano de Buenos Aires,
Gascon 450, Ciudad Autonoma de Buenos Aires, Argentina
e-mail: andreskohan1@gmail.com

M. P. Martinez-Corvalan
Department of ENT, Hospital Italiano de Buenos Aires, Gascon
450, Ciudad Autonoma de Buenos Aires, Argentina

N. Cacchiarelli · C. G. Wahren
Department of Pediatrics, Hospital Italiano de Buenos Aires,
Gascon 450, Ciudad Autonoma de Buenos Aires, Argentina

Five days later, he presented to our hospital complaining of asthenia and cervical pain. Physical examination revealed enlarged cervical lymph nodes, neck stiffness, and a right-sided oropharyngeal mass. The child was febrile with a white blood cell count of $15,000/\text{mm}^3$ and a negative monostest. Cervical US showed bilateral enlarged lymph nodes without fluid collections. Suspecting a retropharyngeal abscess, a neck CT scan with IV contrast under general anesthesia was performed. Imaging findings were typical of an ICA PSA without signs of infections or abscesses (Fig. 1). He was admitted and IV antibiotics (ampicillin/sulbactam 150 mg/kg per day) were initiated. A mini-invasive treatment was preferred rather than neck surgery in this child. Therefore, angiography followed by percutaneous PSA treatment with thrombin injection was decided. Informed consent was obtained from the parents.

Carotid angiography (Fig. 2A) was performed under general anesthesia in the angiographic suite followed by endovascular placement of a 5-mm \times 40-mm angioplasty balloon catheter (Powerflex[®], Cordis, Netherlands) in the ICA lumen. Direct puncture of the PSA under Doppler US guidance was performed with a 22-gauge Chiba needle (Fig. 2B, C). Subsequently, 3 ml (500 U/ml) of human thrombin (Tissuocol Kit[®], Baxter, Austria) were injected inside the PSA after inflation of the carotid angioplasty balloon to avoid intra-arterial migration. The patient was administered IV heparin to achieve an activated clotting time >250 s. After confirmation of PSA occlusion by

Doppler US and angiography (Fig. 2D), the procedure was ended.

The child remained asymptomatic, but a Doppler US 48 h after the intervention showed PSA recurrence, therefore requiring further treatment. Informed consent was obtained from the parents to proceed with endovascular stent-graft placement.

Under general anesthesia, a carotid angiography was performed by transfemoral approach confirming the Doppler US findings (Fig. 3A). Intravenous heparin was administered to achieve an activated clotting time >250 s. A 6-mm \times 40-mm PTFE stent-graft (Viabahn, Gore, Arizona, USA) was placed in the ICA across the PSA. Immediate carotid angiographic control confirmed exclusion of the PSA (Fig. 3B). Follow-up was uneventful with serial postoperative Doppler US controls showing resolution of the PSA.

Eight days after admission, the patient was discharged with antibiotic treatment until 2 weeks were completed. Antiplatelet aggregation (Clopidogrel 19 mg/day and aspirin 50 mg/day) was prescribed for 12 weeks, continuing aspirin for 12 months. MDCT at 1-year follow-up confirmed ICA patency and disappearance of the PSA (Fig. 4). The patient is asymptomatic with ICA patency evidenced by periodic Doppler US at 4 years follow-up.

Discussion

The largest study population of patients with ICA PSA secondary to throat infection was reported in the preantibiotic era [4]. After the introduction of antibiotics and its spread worldwide, it became a rare complication, with few case reports in the medical literature [2, 5, 7–9]. For this reason, carotid PSA is seldom suspected in a child with a pharyngeal mass and a recent history of throat infection, even in the presence of epistaxis [8]. Timely diagnosis is of the utmost importance, not only to prevent a life-threatening hemorrhage, but also to preclude hazardous interventions, such as aspiration or drainage of a wrongly assumed abscess [2, 3].

Prompt and correct diagnosis of ICA PSA is easy and straightforward by imaging studies, provided clinical suspicion. Doppler US typically is the initial imaging study that needs to be performed. In this case report, a conventional US was performed, because neither the clinician nor the radiologist suspected a PSA. Other imaging studies, such as MDCT, can be helpful and diagnostic, as was in our case, offering high resolution and detailed anatomic depiction.

Appropriate treatment should be rapidly performed after diagnosis to prevent a life-threatening hemorrhage [2, 6–8]. Decades ago, the only plausible treatment was surgical

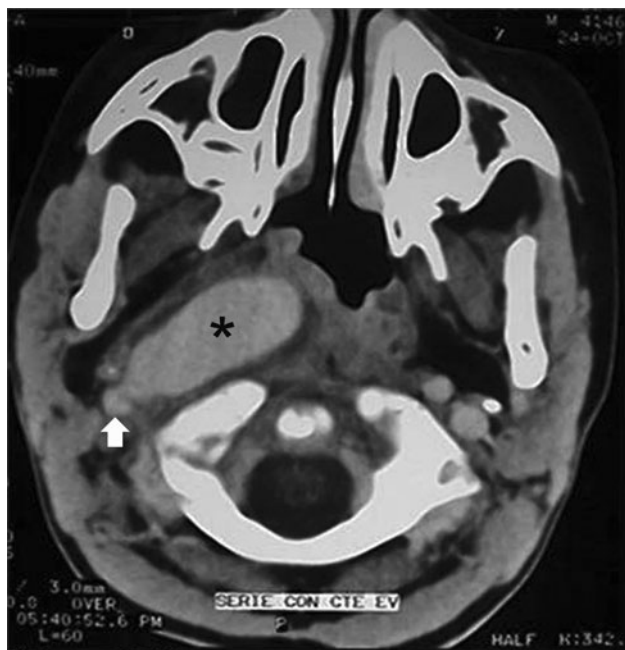

Fig. 1 CT scan shows a pseudoaneurysm (*) from the internal carotid artery (arrow) displacing the oropharynx

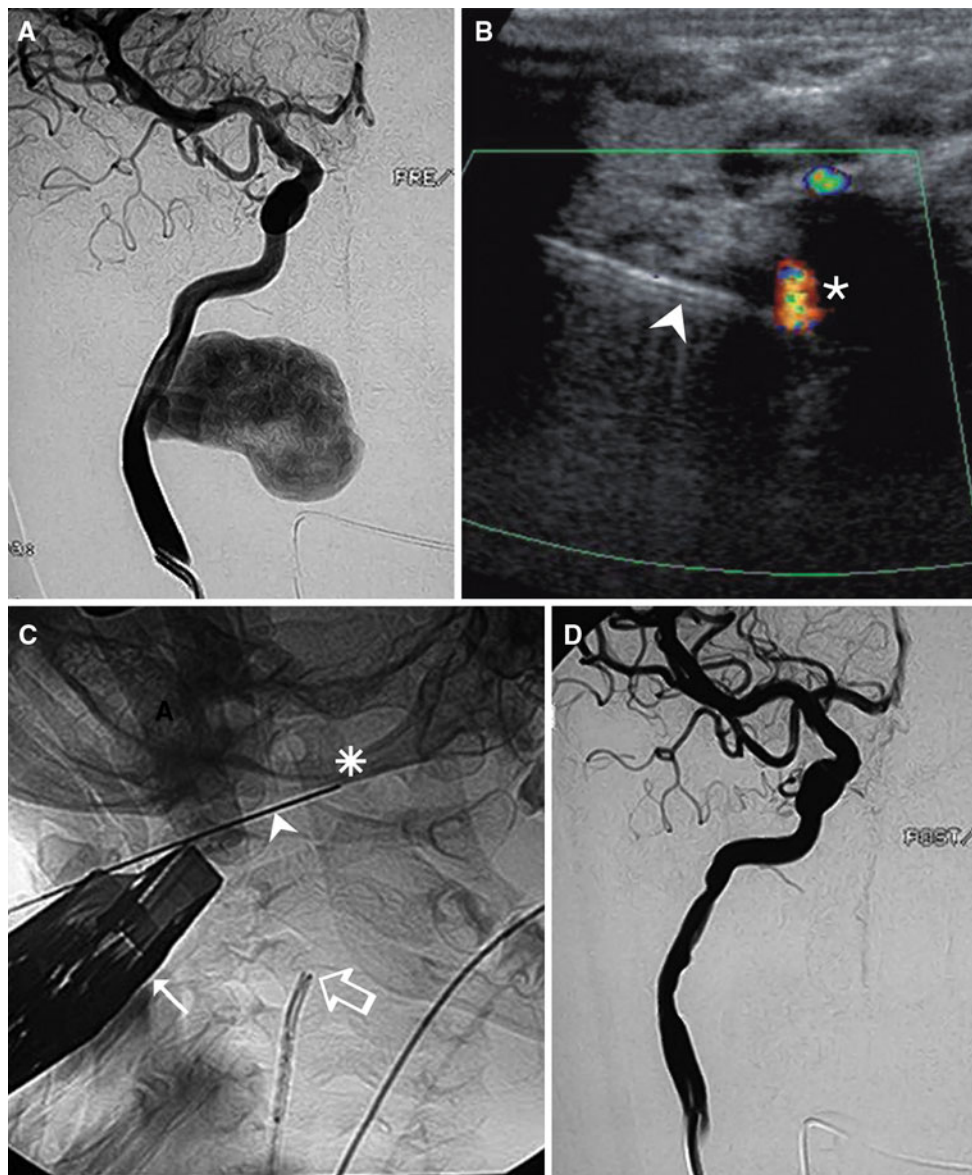


Fig. 2 Angiography and thrombin pseudoaneurysm (PSA) injection. **A** Carotid angiography in anteroposterior (AP) view shows the PSA. US Doppler (**B**) and X-ray (**C**) show the US probe (*arrow*), the

percutaneous needle (*arrowhead*) inside the PSA (*) for thrombin injection, and the internal carotid artery catheter (*open arrow*). **D** Control carotid angiography in AP view no longer shows the PSA

carotid arterial ligation, which was associated with a high incidence of adverse events [2, 4]. Eventually, it was replaced by endovascular occlusion with detachable balloons or other embolic materials [5, 6, 9, 10]. Although endovascular exclusion with this technique is usually safe and curative [5, 9], the patency of the involved ICA remains hampered for life, generating a small risk for aneurysmal disease in the contralateral ICA due to chronic increased blood flow [11]. Selective embolization of the PSA may be too hazardous because of the fragile nature of its wall [6, 10].

Stent graft placement has been reported for carotid PSA treatment [7]. However, it was not considered as a first

option because of concerns regarding long-term outcome and adaptability of the growing carotid artery to the covered stent. Also there is the controversy as to whether the use of a stent-graft in a recently infected area contributes to chronic infection [7].

Percutaneous thrombin injection has been reported successful for treating PSA located in peripheral arteries in both adults and children [12]. Only one case of ICA PSA successfully treated with this technique has been reported but in an adult patient [13]. The benefits of this technique are many (e.g., lack of use of foreign material and unaltered flow of the affected ICA) and far outweigh the risks (e.g., intra-arterial migration). In the case herein reported,

Fig. 3 **A** Carotid angiography in anteroposterior (AP) view at 48 h after thrombin injection shows pseudoaneurysm (PSA) partial recurrence. **B** Control carotid angiography in AP view after stent-graft placement shows complete exclusion of the PSA from the circulation, with normal-caliber internal carotid artery and good intracerebral flow

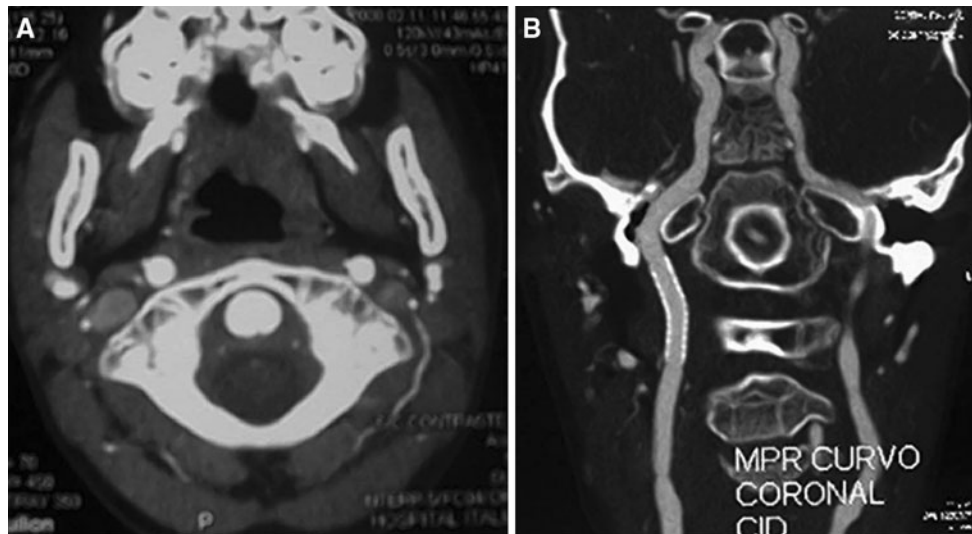
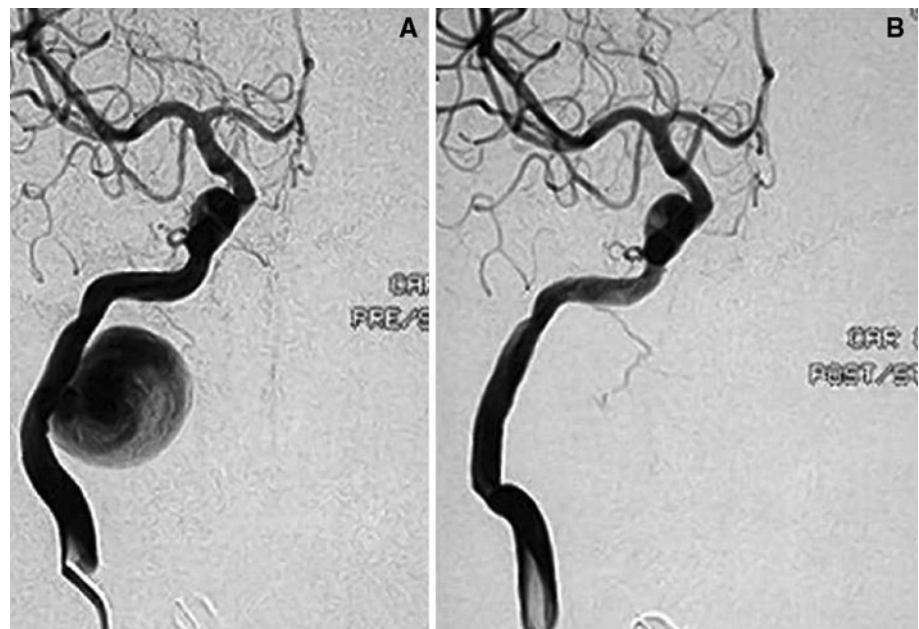


Fig. 4 **A** Normal axial MDCT at 12 months follow-up. Compare with Fig. 1. **B** MPR MDCT shows the stent-graft and the patent right internal carotid artery at 12 months follow-up

the PSA neck was previously occluded with an endovascular angioplasty balloon to avoid distal migration of the thrombin during injection, as suggested by some authors [14].

Although initially successful, recurrence of the PSA was noticed by US Doppler 48 h after the procedure. No definite explanation was found for this treatment failure. Interesting enough, Sheiman et al. suggested that early recanalization of femoral PSA after thrombin injection might be related to wall laceration or previous infection [14].

Given that reinjection of thrombin could not ensure a definite occlusion of the PSA [14], it was decided to treat

the PSA with stent-graft placement, because the benefits were now considered to outweigh the risks in this child with previous thrombin injection failure. Immediate occlusion of the PSA was observed in both angiography and US Doppler. Antibiotics were given to further reduce the risk of stent-graft infection, as reported [5].

In conclusion, a recent history of throat infection and epistaxis in a child should raise the suspicion of an ICA PSA, especially in the presence of an oropharyngeal protruding mass. Confirmation of the diagnosis is simple with imaging studies, such as Doppler US or MDCT. An ICA PSA is a life-threatening clinical situation that urges prompt treatment by interventional radiology techniques or

surgery. Although thrombin injection was technically feasible and initially successful, subsequent recanalization determined treatment failure. An alternative treatment with carotid stent-graft placement proved to be safe and successful in this patient at 4 years follow-up.

Conflict of interest None.

References

- Liston R (1843) On a variety of false aneurysms. *Br Foreign Med Rev* 15:155–161
- Pearson SE, Choi SS (2005) Pseudoaneurysm of the internal carotid artery: a case report and review of the literature. *Arch Otolaryngol Head Neck Surg* 131:454–456
- Lasjaunias P (1997) Vascular diseases in neonates, infants and children. In: Lasjaunias P (ed) *Interventional neuroradiology management*. Springer, Berlin
- Salinger S, Pearlman S (1933) Hemorrhage from pharyngeal and peritonsillar abscesses. Report of cases, resume of literature and discussion of the ligation of the carotid artery. *Arch Otolaryngol* 18:464–509
- Reisner A, Marshall GS, Bryant K et al (1999) Endovascular occlusion of a carotid pseudoaneurysm complicating deep neck space infection in a child. Case report. *J Neurosurg* 91(3): 510–514
- Garcia-Monaco R, Lasjaunias P, Alvarez H, Rodesch G (1993) Embolization of vascular lesions of the head and neck. In: Valavanis A (ed) *Interventional neuroradiology*. Springer, Berlin
- Gralla J, Brekenfeld C, Schmidli J et al (2004) Internal carotid artery aneurysm with life-threatening hemorrhages in a pediatric patient: endovascular treatment options. *J Endovasc Ther* 11: 734–738
- Fernández CA, Tagarro S, Lozano-Arnilla CG et al (2005) Internal carotid pseudoaneurysm within a parapharyngeal infection: an infrequent complication of difficult diagnosis. *Otolaryngol Head Neck Surg* 132(4):671–673
- Brochu B, Dubois J, Garel L et al (2004) Complications of ENT infections: pseudoaneurysm of the internal carotid artery. *Pediatr Radiol* 34:417–420
- Crow WN, Scott BA, Guinto FC Jr et al (1992) Massive epistaxis due to pseudoaneurysm treated with detachable balloons. *Arch Otolaryngol Head Neck Surg* 118:321–324
- Timperman PE, Tomsick TA, Tew JM Jr, van Loveren HR (1995) Aneurysm formation after carotid occlusion. *AJNR Am J Neuroradiol* 16:329–331
- Tisi PV, Callam MJ (2009) Treatment for femoral pseudoaneurysms. *Cochrane Database Syst Rev* CD004981
- Holder R, Hilton D, Martin J et al (2002) Percutaneous thrombin injection of carotid artery pseudoaneurysm. *J Endovasc Ther* 9:25–28
- Sheiman RG, Mastromatteo M (2003) Iatrogenic femoral pseudoaneurysms that are unresponsive to percutaneous thrombin injection: potential causes. *AJR Am J Roentgenol* 181:1301–1304